

Clinico-radiological Spectrum of COVID-19 Associated Rhino-cerebral Mucormycosis: A Retrospective Cohort Study from a Tertiary Care Hospital

ALKA AGRAWAL¹, NEETU KORI², YOGITA DIXIT³, PRAKHAR NIGAM⁴, MRINAL CHOUDHARY⁵, SILKY TAYA⁶

ABSTRACT

Introduction: Rhino-cerebral Mucormycosis (RCM), in the pre-Coronavirus Disease-2019 (COVID-19) era, was thought to be solely associated with an immunocompromised state. However, an unforeseen outbreak in the number of mucormycosis cases was seen with the increase in Severe Acute Respiratory Syndrome Coronavirus 2 (SARS-CoV-2) infection.

Aim: To study and investigate the clinical characteristics, imaging findings, associated risk factors, and clinical outcomes in COVID-19 associated mucormycosis.

Materials and Methods: A retrospective cohort study was conducted comprising 480 cases of COVID-19 associated mucormycosis who presented to the institution between April 2020 and September 2020. The clinical and radiological data were studied and analysed.

Results: Out of a total of 480 cases, 443 (92.29%) were found to suffering from diabetes mellitus and 392 patients (81.66%) had a history of steroids intake in the studied population. Facial or per orbital swelling followed by pain were the most frequent

presenting complaints found in 188 (39.16%) and 162 (33.75%) patients, respectively. Nasal septum and middle turbinate were the most common sites of disease involvement on nasal endoscopic examination. On radiological imaging, maxillary (438; 91.25%) was the most commonly involved sinus followed by ethmoids (395; 82.29%). Premaxillary/retroantral fat and orbits were the most common sites of extra sinonasal spread of infection found in 278 (57.91%) and 244 (50.83%) patients, respectively. About 238 (49.58%) patients showed bony erosion and dehiscence. Intracranial complications were seen in 73 (15.21%) patients. Glycated Haemoglobin (HbA1c) levels showed significant value with higher disease staging. Oxygen supplementation was frequently associated with extrasinus spread of infection. A total of 44 (9.17%) patients succumbed to death despite aggressive antifungal treatment.

Conclusion: COVID-19 associated RCM shows frequent and extensive spread to extrasinus regions, especially with uncontrolled diabetes mellitus, steroid administration, and oxygen supplementation. High clinical suspicion, early imaging, and prompt institution of antifungal therapy can aid in reducing mortality rate.

Keywords: Coronavirus disease-2019, Diabetes mellitus, Magnetic resonance imaging

INTRODUCTION

Since the onset of the pandemic in 2020, the world has seen millions of people succumb to death due to COVID-19 and related complications [1]. The complications of COVID-19 overwhelmed healthcare facilities worldwide and led to the re-emergence of many opportunistic infections. During the second wave of SARS-CoV-2 infection, India witnessed a dramatic increase in RCM [2]. It is an invasive fungal infection that is known to cause high morbidity and mortality. Diabetic ketoacidosis, severe burns, steroid therapy, solid organ transplantation, prolonged corticosteroid therapy, haemochromatosis, patients with Human Immunodeficiency Virus (HIV), neutropenia, malnutrition, and haematologic malignancies predispose individuals for this opportunistic infection [3]. India, home to more than 70 million diabetics, the second-highest globally, had an 80 times higher prevalence of mucormycosis in the pre-COVID era itself [4]. The unholy trinity of high burden of diabetes, immunomodulation associated with COVID-19, and rampant use of steroids for treatment led to a rapid upsurge in the RCM cases.

The causative agent of the RCM is saprophytic fungi of the order *Morales* [5]. Inhalation of spores followed by germination in the nasal cavity is the usual mode of infection. Rapid progression of the infection into surrounding soft tissue, orbit, and brain occurs due to its tendency to invade blood vessels [6]. The extent of nasal and para nasal sinus involvement could be assessed by clinical and endoscopic examination. However, the extension into neck spaces, orbit, and brain remains a mystery unless the patient presents

with overt features. Imaging plays a crucial role in the recognition of deeper extension of infection which is blind to clinicians' eyes. The good prognosis of mucormycosis lies in early diagnosis and appropriate management. Early identification of disease is possible with the identification of associated clinical and radiological features in the setting of predisposing factors. The study of clinical characteristics, imaging findings, associated risk factors, and clinical outcomes help in a better understanding of the disease pathology. In our tertiary care hospital, authors conducted one of the largest single-centre studies on RCM using clinical and radiological data of 480 patients to describe the clinical features, risk factors and clinical outcome. The study also aimed to stage the patients on the basis of imaging findings and the association of disease severity with the clinical risk factors.

MATERIALS AND METHODS

A retrospective cohort study comprising of 480 consecutive patients who had a history of COVID-19 and were diagnosed with sinonasal mucormycosis was conducted after approval from the Institutional Ethics and Scientific Review Committee in M.Y. Hospital, Indore (IRB approval No. 03/22). Patients' data including demography, clinical findings, blood investigations, endoscopic and imaging findings were assessed who presented to our tertiary care institution between April 2020 and September 2020. The analysis of the data was done from January 2022 to February 2022. Follow-up data was available till three months after the discharge from the hospital.

Inclusion criteria: A positive Reverse Transcriptase-Polymerase Chain Reaction (RT-PCR) test or COVID-19 reporting and data system (CO-RADS) grade 5 and histopathologically or microbiologically diagnosed cases with sinonasal mucormycosis were included in the study.

Exclusion criteria: Patients who did not undergo Magnetic Resonance Imaging (MRI) or whose follow-up details were not available were excluded.

Study Procedure

All documented microbiological and pathological investigations were carried out in the institutional laboratories. The stated co-morbidities, presenting complaints, clinical examination findings, laboratory parameters, past treatment history, and outcomes were thoroughly studied, compiled, tabulated, and analysed. Radiological imaging of all patients was performed in the institutional 3T MRI machine. Imaging data were acquired through hospital Picture Archiving and Communication System (PACS). Images were analysed at the workstation and reports were prepared using a dedicated format for RCM. Patients were segregated on the basis of the radiological staging of the disease. Stage I was defined as lesions confined to sinonasal cavities. Stage II represented the involvement of perinatal fat, neck spaces, pterygopalatine fossa, bone, and orbit. Patients with radiological evidence of intracranial spread of infection were labelled as stage III [7].

STATISTICAL ANALYSIS

All clinical and radiological imaging data were tabulated and comparisons were done using International Business Machines (IBM) Statistical Package for the Social Sciences (SPSS) software for Windows, Version 26.0. Armonk, NY: IBM Corp. The mean and Standard Deviation (SD) of the quantitative variables were calculated. A Chi-square test was used for the comparison of categorical variables. One-way Analysis of Variance (ANOVA) was used to find association between patients' clinical parameters and the radiological stage of the disease. The p-values <0.05 were considered statistically significant.

RESULTS

The most commonly affected patients belonged to the age group of 41-50 years. The mean age of the studied patients was 48.40 years, with a slight male preponderance (250;52%). The duration between COVID-19 and the appearance of symptoms related to RCM ranged from 2-8 weeks. Diabetes mellitus was the most commonly associated risk factor followed by the history of steroid therapy [Table/Fig-1].

Risk factors	Number of patients (%)
Diabetes mellitus	443 (92.29)
History of steroid administration	392 (81.66)
History of oxygen support	155 (32.29)
History of remdesvir therapy	86 (17.91)
History of tocilizumab therapy	28 (5.83)
Patients with haematological malignancies	12 (2.5)
Post organ transplantation patients	7 (1.45)

[Table/Fig-1]: Risk factors for COVID-19 associated mucormycosis.

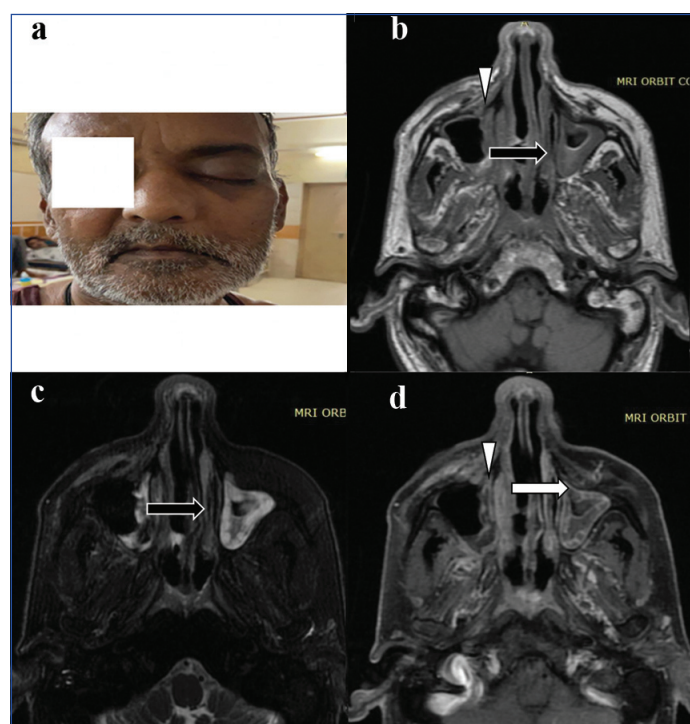
The most common primary complaints were facial or periorbital swelling, seen in 188 patients (39.16%), followed by facial or periorbital pain in 162 patients (33.75%), nasal blockage in 50 (10.41%) patients, headache in 22 (4.58%), diminution of vision in 18 (3.75%), nasal discharge in 17 (3.54%), ptosis in 15 (3.12%), and others like epistaxis, toothache in 8 (1.67%) patients. The diminution of vision was associated with corneal haze, uveitis, optic disc edema, vitreous haemorrhage, retinal detachment, diabetic retinopathy, and central retinal artery occlusion as observed during ophthalmologic examination. Out of 480, 387 (80.62%) underwent diagnostic

nasal endoscopy. Nasal septum and middle turbinate were the most common sites of disease pathology seen in 320 (82.68%) and 270 (69.76%) patients, respectively. The major endoscopic finding was mucosal discoloration (117;30.23%) with or without the presence of discharge. Nasal secretions with mucosal oedema were seen in 98 (25.32%) patients, while characteristic black scars were noted in 54 (13.95%) patients who underwent nasal endoscopy.

All 480 patients underwent combined MRI of the sinonasal, orbit, and brain. The most commonly involved sinuses on MRI were maxillary followed by ethmoid [Table/Fig-2]. Bilateral involvement of sinuses was more common (330;68.75%) than unilateral disease [Table/Fig-3]. Premaxillary/retroantral fat and orbits were the most common

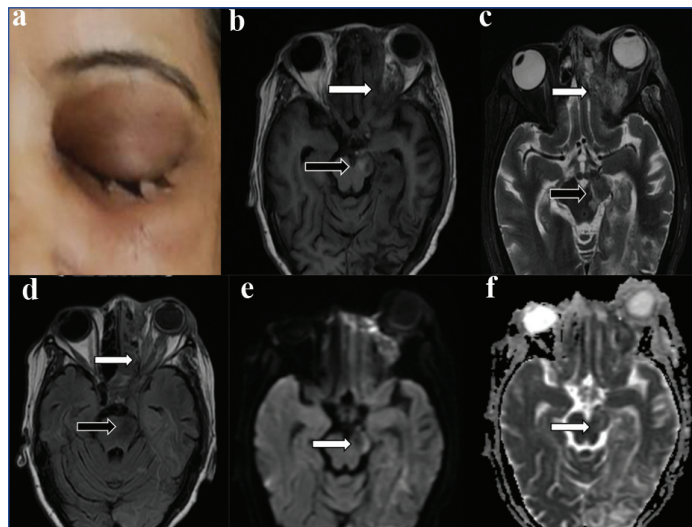
Site of involvement		Number	Percentage
Sinuses	Maxillary	438	91.25
	Ethmoid	395	82.29
	Sphenoid	266	55.41
	Frontal	156	32.50
Spaces	Pre/retro maxillary fat	278	57.91
	Masticator space	180	37.50
	Pterygopalatine fossa	106	22.08
Orbits (n=244) (50.83%)	Extraconal compartment	242	50.41
	Extraocular muscles	210	43.75
	Intraoral compartment	174	36.25
	Orbital apex	65	13.54
Bone		238	49.58
Intracranial (n=73) (15.21%)	Meninges	52	10.83
	Cavernous sinus	37	7.70
	Internal carotid artery	22	4.58
	Cerebritis	22	4.58
	Abscess	20	4.16
	Infarct	18	3.75
	Trigeminal nerve	5	1.04

[Table/Fig-2]: MRI features of studied patients with Rhino-cerebral mucormycosis.

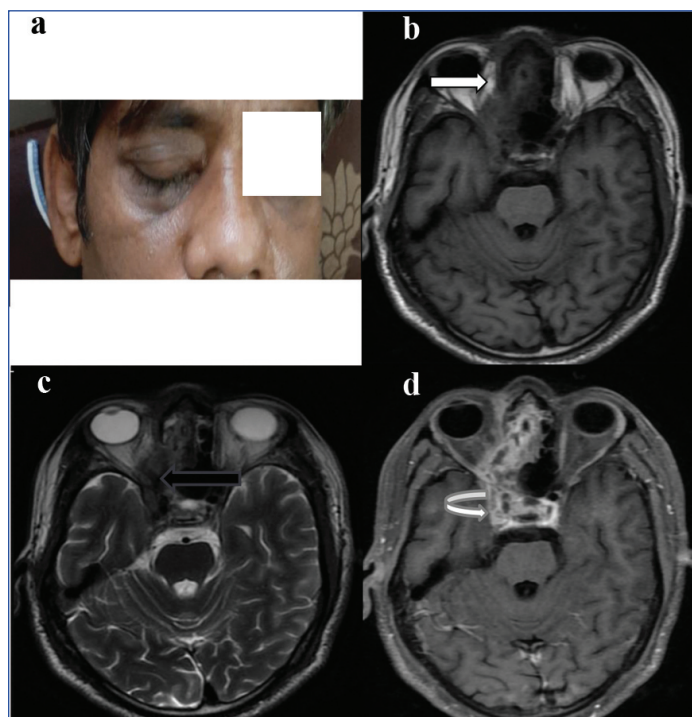


[Table/Fig-3]: Rhinocerebral mucormycosis. A 52-year-old diabetic patient with a history of intake of steroids for COVID illness presented with left-sided facial pain and swelling for last 10 days (a). Axial T1-weighted image (b), axial T2-weighted fat-saturated image (c), and axial T1 fat-saturated post-contrast images (d) show T1 hypointense and T2 hyperintense lesion in bilateral maxillary sinuses (black arrows) with the erosion of posterior wall of right maxillary sinus (white arrowheads) showing peripheral enhancement (white arrow). There is also associated left pre-maxillary soft tissue thickening.

sites of extra sinonasal spread of infection found in 278 (57.91%) and 244 (50.83%) patients, respectively. Bone erosion or dehiscence was seen in 238 (49.58%) patients. The most common sites of erosion were lamina papyracea and posterior maxillary sinus walls. Intracranial signs [Table/Fig-4] of mucormycosis were seen in 73 (15.21%) patients, the most common being pachymeningitis (52;10.83%) and cavernous sinus thrombosis/thrombophlebitis (37;7.70%) [Table/Fig-5].



[Table/Fig-4]: Rhino-cerebral mucormycosis with orbital and intracranial involvement. A 40-year-old female with a history of intake of steroids for the last 1 month presented with left eyelid and per orbital swelling (a). Axial T1-weighted image (b) shows heterogeneous hypointense lesion in left ethmoid sinuses extending laterally into the left retrobulbar region (white arrows) through the medial orbital wall causing protrusion of left eye globe and involvement of orbital apex. There is another T1-hypointense lesion seen in the left midbrain (black arrow). The orbital (white arrows) and mid-brain (black arrows) lesions appear hyperintense on the axial T2 weighted image (c) and hypointense on the FLAIR image (d). Axial diffusion-weighted (e) and apparent diffusion coefficient images (f) show peripheral restriction of the midbrain lesion (white arrows) suggesting late cerebritis.



[Table/Fig-5]: Rhino-cerebral mucormycosis with involvement of orbit and brain. 41-year-old diabetic patient having right lid swelling and right periorbital swelling (a). Axial T1-weighted (b) and T2-weighted images (c) show lesion involving right ethmoid sinus (white arrow) and right orbital apex (black arrow). Axial T1-weighted postcontrast image (d) shows heterogeneous enhancement of the right ethmoidal mucosa and orbital apex along with non-enhancing soft tissue in the right cavernous sinus (white curved arrow) with convex outward margin, suggestive of cavernous sinus thrombosis.

The stage I disease i.e. rhino mucormycosis without extra sinus spread was present in 190 (39.58%) patients while stage II and III were seen in 217 (45.21%) and 73 (15.20%) patients, respectively. Ninety-seven (44.70%) out of 217 patients diagnosed with stage II disease on

MRI, had no specific signs or symptoms of ocular involvement during clinical assessment. There was a significant association between HbA1c levels and disease staging [Table/Fig-6]. The patients who received steroids and oxygen supplementation during COVID-19 showed higher stages of fungal infection [Table/Fig-7].

Stage of the disease	Mean HbA1c values	p-value
Stage-I (n=190)	7.01±0.54	<0.001
Stage-II (n=217)	8.46±0.25	
Stage-III (n=73)	9.18±0.24	

[Table/Fig-6]: Mean HbA1c values of patients with different stages.

One-way Analysis of Variance (ANOVA); p-value of <0.05 was considered significant

Risk factors		Stage-I (n=190)	Stage-II (n=217)	Stage-III (n=73)	p-value
History of steroid administration	Present (n=392)	144	182	66	0.01
	Absent (n=88)	46	35	7	
History of oxygen supplementation	Present (n=155)	76	65	14	0.003
	Absent (n=325)	114	152	59	

[Table/Fig-7]: Association of risk factors and radiological staging among patients with COVID-19 associated mucormycosis.

Chi-square test; p-value <0.05 was considered significant

All patients received intravenous liposomal amphotericin B for an average duration 19 days (10-32 days). The average duration of hospital stay was 18 days (14-40 days). All patients irrespective of the stage underwent nasal debridement with or without functional endoscopic sinus surgery and received liposomal amphotericin B. Patients with ocular involvement were given Transcutaneous Retro bulbar Amphotericin B (TRAMB) injections. Patients with MRI evidence of orbital involvement but with no ocular complaints were injected once in seven days while those with complaints were given daily injections. Out of a total of 244 patients with the orbital disease, 196 (80.33%) patients showed marked improvement in terms of ocular movement and visual acuity. Twenty (8.20%) patients showed minimal improvement while the rest 28 (11.47%) patients underwent orbital exenteration. Eighteen patients succumbed to death post exenteration. Overall, a total of 44 (9.17%) patients died despite aggressive antifungal therapy and surgical debridement.

DISCUSSION

The order Mucorales are known for their aggressive angioinvasive nature in the presence of favorable host factors. Immunocompromised individuals are unable to mount a sufficient immune response to evade the fungal infection and therefore are at risk. The fungi begin their journey in the human body through germination and invasion of inhaled spores. The association of COVID-19 and RCM is now well known. COVID-19 causes a variety of immunological alterations such as decrease in number and impaired function of CD8+, CD4+, natural killer, and dendritic cells [8,9]. Recent literature suggests an increased expression of glucose-related protein 78 (GRP 78) in COVID-19 patients [10]. Mucorales gain access to the epithelial and endothelial cells by binding to this receptor [11]. Furthermore, high blood glucose levels and ketoacidosis in diabetic patients up regulate GRP-78 expression over the cell surface [11,12]. The corticosteroids widely used for the treatment of COVID-19 cause immunosuppression and hyperglycaemia, further compromising the host defense system. Thus, the triad of steroids, diabetes mellitus, and SARS-CoV-2 infection provides a perfect atmosphere for opportunistic fungal infections.

In present study, facial or per orbital swelling/pain and nasal blockage were the most common primary complaints. The metacentric Collaborative OPAI-IJO study on Mucormycosis In COVID-19 (COSMIC) study showed that orbital/facial pain (23%), orbital/facial oedema (21%), loss of vision (19%), ptosis (11%), and nasal block (9%) are presenting features among patients with

COVID-19 associated mucormycosis [13]. The study by Dubey S et al., revealed headache, ptosis/proptosis, retro-orbital pain, facial numbness in 81.81%, 78.18%, 61.82% and 56.36% of patients, respectively [14]. Several studies including present study found maxillary and ethmoid sinuses as the most commonly affected paranasal sinuses [7,15,16].

The extra sinus spread of infection to per maxillary/retroantral fat and orbits was commonly observed in present study. Mangal R et al., also found fungal spread to retro maxillary fat and orbit in 50.74% and 40.25% of patients, respectively [15]. The fungal invasion of blood vessels allows the perivascular spread of infection across the bony walls of sinuses [7]. The invading hyphae also damages the endothelial lining of blood vessels leading to clot formation, which results in ischaemia and necrosis of the surrounding tissue [6]. The ischaemia appeared as discoloration of nasal mucosa during endoscopy, which on complete devitalisation appeared as black necrotic eschar. Radiologically, ischaemic turbinate is described as black turbinate which is a non enhancement of turbinate on contrast-enhanced MR sequences [17].

Bony erosion or dehiscence is also a common phenomenon in mucor infection. In present study, it was seen in 238 out of 290 patients with extra sinus lesions. The lamina papyracea and inferior orbital wall were common sites of erosion allowing easy access to orbital soft tissue. Few cases with orbital infection also had lesions in the nasolacrimal duct suggesting ascend of infection through the duct. Cases with intact bony walls and normal duct probably had extension through perivascular/per neural routes.

Ophthalmoplegia was associated with the extraocular muscle involvement mainly along the floor and medial wall of the orbit. Orbital apex involvement in the form of fat stranding or soft tissue at the apex on MRI was clinically associated with complete ophthalmoplegia and variable loss of vision. However, in RCM, the clinical complaints do not necessarily correlate with the severity of the disease. Ninety-seven patients in present study had no specific ocular signs and symptoms but were detected with orbital lesions on MRI. Radiologically, lesions of extraocular muscles, retro-orbital fat, orbital apex, and cavernous sinus though infrequent but were seen without any diplopia or ophthalmoplegia. Similarly, pachymeningitis was not associated with any nuchal rigidity, probably due to focal meningeal involvement. A high index of suspicion and early radiological imaging allows timely detection of such complications.

Cavernous sinus thrombosis/thrombophlebitis was one of the most common intracranial manifestations in present study. Previous studies on radiological spectrum of COVID-19 associated mucormycosis also showed the involvement of cavernous sinus with an intracranial spread of infection [15,16,18]. Fungal hyphae can gain access to various nerves traversing the cavernous sinus and spread along the fibres to the brainstem or skull base [19]. The trigeminal nerve was the most commonly affected nerve in present study. Abnormal enhancement on contrast-enhanced images and restriction on diffusion-weighted imaging suggested its involvement. Arteritis and thrombosis of the cavernous part of the internal carotid artery were common with cavernous sinus lesions. Consequently, with arterial access, cerebral infarct may occur. Cavernous sinus thrombophlebitis/thrombosis has a snowball effect with respect to intracranial complications and is an ominous sign. Therefore, it is prudent to identify clinical and radiological features of cavernous sinus involvement for better clinical outcomes.

In present study, 60.42% of patients presented with stage II/III lesions. The higher stages of disease were strongly associated with increased serum HbA1c levels ($p < 0.001$). Yadav T et al., also found a significant correlation between HbA1c level and disease stage ($p < 0.005$) [18]. Hence, it is crucial to achieve adequate glycaemic control apart from administering standard antifungal regimens to limit fungal invasion, especially in diabetics.

In present study, 32.29% of patients had a history of oxygen supplementation during the treatment of COVID-19. It also showed a significant association with the disease severity. During the second wave of COVID-19 healthcare facilities were overwhelmed and there was a massive shortage of medical oxygen. The use of industrial oxygen as an alternative, possibly contaminated by rust (an iron-rich fungal growth-promoting substance) could be one of the possible reasons for increased infections [20]. Additionally, damage to the nasal mucosa by repeated suctioning and reapplication and prolonged use of face masks especially in hot and humid Indian weather might have exacerbated the risk.

The overall mortality in the present study was 9.17%, which was far less than studies conducted in the pre-COVID era [21,22]. In COVID-19 associated RCM, the overall mortality has been estimated to be 31%. The lower mortality rate in present study was comparable to those stated by the COSMIC study group (14%) and could be attributed to increased awareness among the patients and, aggressive and early interventions by the clinicians [13]. Furthermore, present study was conducted in a tertiary healthcare facility that had a dedicated hospital for COVID-19 and related complications. Specialists from otorhinolaryngology, ophthalmology, dentistry, neurology, radiology, pathology, and microbiology departments coordinated and were available round the clock for patient care. The study provides one of the largest single-centre data on clinical and radiological features along with the clinical outcomes of COVID-19 associated RCM.

Limitation(s)

First, a large percentage of patients in present study had extra sinonasal complications which could be due to selection bias as our institute is a tertiary referral centre. Second, due to the variation in the duration and the type of treatment provided, the correlation between clinical risk factors and disease outcome was not performed. Third, due to a lack of documentation and/or MR images, a large sum of patients were excluded from the study analysis. Lastly, present study included only those patients, who suffered from COVID-19. The patients without any history of COVID illness may show a different clinical picture and radiological features. Future prospective multicentric studies with serial assessment of clinical and imaging data as well as of long-term outcomes and complications of RCM are required for a better understanding of the disease process.

CONCLUSION(S)

The clinical presentation of RCM has a broad spectrum. MRI being multiplanar imaging provides adequate information about the spread of disease. Orbits and fat surrounding the maxillary antrum, are frequent sites of disease spread. Orbital and intracranial lesions should be actively looked upon as they are associated with treatment measures used during COVID-19 and high glycaemic index. Judicious use of steroids, adequate glycaemic control, and standard hygiene measures during oxygen supplementation could reduce the risk of COVID-19 associated RCM. High clinical suspicion and prompt application of diagnostic methods remain fundamental for the identification of disease in its nascent stage. A robust multidisciplinary approach with a dedicated team of clinicians is vital for superior results in terms of morbidity and mortality associated with RCM.

REFERENCES

- [1] WHO Coronavirus (COVID-19) Dashboard [Internet]. Covid19.who.int. 2022 [cited 16 March 2022]. Available from: <https://covid19.who.int/>.
- [2] Singh AK, Singh R, Joshi SR, Misra A. Mucormycosis in COVID-19: A systematic review of cases reported worldwide and in India. *Diabetes & Metabolic Syndrome: Clin Res Rev.* 2021;15(4):102146.

- [3] Gonzalez CE, Couriel DR, Walsh TJ. Disseminated zygomycosis in a neutropenic patient: Successful treatment with amphotericin B lipid complex and granulocyte colony-stimulating factor. *Clin Infect Dis*. 1997;24(2):192-96.
- [4] Mucormycosis [Internet]. Who.int. 2022 [cited 16 March 2022]. Available from: [https://www.who.int/india/emergencies/coronavirus-disease-\(covid-19\)/mucormycosis#:~:text=Disease%20burden&text=In%20India%2C%20prevalence%20of%20mucormycosis,%2F851%20\(46%25\)%20patients.s](https://www.who.int/india/emergencies/coronavirus-disease-(covid-19)/mucormycosis#:~:text=Disease%20burden&text=In%20India%2C%20prevalence%20of%20mucormycosis,%2F851%20(46%25)%20patients.s).
- [5] Brown SR, Shah IA, Grinstead M. Rhinocerebral mucormycosis caused by *Apophysomyces elegans*. *Am J Rhinol*. 1998;12(4):289-92.
- [6] Bhandari J, Thada P, Nagalli S. Rhino cerebral mucormycosis. Stat Pearls Publishing, Treasure Island (FL); 2020.
- [7] Rupa V, Maheswaran S, Ebenezer J, Mathews SS. Current therapeutic protocols for chronic granulomatous fungal sinusitis. *Rhinology*. 2015;53:181-86.
- [8] Zhou R, To KKW, Wong YC, Liu L, Zhou B, Li X, et al. Acute SARS-CoV-2 infection impairs dendritic cell and T cell responses. *Immunity*. 2020;53(4):864-77.
- [9] Diao B, Wang C, Tan Y, Chen X, Liu Y, Ning L, et al. Reduction and functional exhaustion of T cells in patients with Coronavirus Disease 2019 (COVID-19). *Front Immune*. 2020;11:827.
- [10] Sabirli R, Koseler A, Goren T, Trucker I, Kurt O. High GRP78 levels in Covid-19 infection: A case-control study. *Life Sci*. 2021;265:118781.
- [11] Liu M, Spellberg B, Phan QT, Fu Y, Fu Y, Lee AS, et al. The endothelial cell receptor GRP78 is required for mucormycosis pathogenesis in diabetic mice. *J Clin Invest*. 2010;120:1914-24.
- [12] Baldin C, Ibrahim AS. Molecular mechanisms of mucormycosis-The bitter and the sweet. *PLOS Pathog*. 2017;13:e1006408.
- [13] Sen M, Honavar SG, Bansal R, Sengupta S, Rao R, Kim U, et al. Epidemiology, clinical profile, management, and outcome of COVID-19-associated rhino-orbital-cerebral mucormycosis in 2826 patients in India—Collaborative OPAL-IJO Study on Mucormycosis in COVID-19 (COSMIC), Report 1. *Indian J Ophthalmic*. 2021;69(7):1670-92.
- [14] Dubey S, Mukherjee D, Sarkar P, Mukhopadhyay P, Barman D, Bandopadhyay M, et al. COVID-19 associated rhino-orbital-cerebral mucormycosis: An observational study from Eastern India, with special emphasis on neurological spectrum. *Diabetes & Metabolic Syndrome: Clin Res Rev*. 2021;15(5):102267.
- [15] Mangal R, Gehlot PS, Bang A, Kaushal A, Kolare R. COVID-19 associated rhino-orbital-cerebral mucormycosis: Clinical profile and imaging spectrum. *J Clin Diag Res*. 2021;15(9):TC01-06.
- [16] Patel DD, Adke S, Badhe PV, Lamture S, Marfatia H, Mhatre P. COVID-19 associated rhino-orbital-cerebral mucormycosis: Imaging spectrum and clinico-radiological correlation- A single centre experience. *Clinical Imaging*. 2022;82:172-78.
- [17] Safder S, Carpenter JS, Roberts TD, Bailey N. The "Black Turbinate" sign: An early MR imaging finding of nasal mucormycosis. *AJNR Am J Neuroradiol*. 2010;31(4):771-74.
- [18] Yadav T, Tiwari S, Gupta A, Garg PK, Khera PS, Rajagopal R, et al. Magnetic resonance imaging in Coronavirus Disease-2019 Associated Rhino-Orbital-Cerebral Mucormycosis (CA-ROCM)-Imaging analysis of 50 consecutive patients. *Curr Probl Diagn Radiol*. 2022;51(1):112-20.
- [19] Sravani T, Uppin SG, Uppin MS, Sundaram C. Rhino cerebral mucormycosis: Pathology revisited with emphasis on perineural spread. *Neurology India*. 2014;62(4):383.
- [20] Ong JJ, Chan AC, Sharma AK, Sharma S, Sharma VK. The mucormycosis epidemic within COVID-19 pandemic-lessons from India. *Brain, Behavior, and Immunity*. 2021;97:04-05.
- [21] Kennedy KJ, Daveson K, Slavin MA, van Hal SJ, Sorrell TC, Lee A, et al; Australia and New Zealand Mycoses Interest Group of the Australasian Society for Infectious Diseases. Mucormycosis in Australia: Contemporary epidemiology and outcomes. *Clin Microbiol Infect*. 2016;22(9):775-81.
- [22] Palejwala SK, Zangeneh TT, Goldstein SA, Lemole GM. An aggressive multidisciplinary approach reduces mortality in rhinocerebral mucormycosis. *Surg Neurol Int*. 2016;7:61. Doi: 10.4103/2152-7806.182964.

PARTICULARS OF CONTRIBUTORS:

1. Professor and Head, Department of Radiodiagnosis, M.G.M. Medical College and M.Y. Hospital, Indore, Madhya Pradesh, India.
2. Associate Professor, Department of Ophthalmology, M.G.M. Medical College and M.Y. Hospital, Indore, Madhya Pradesh, India.
3. Assistant Professor, Department of Otorhinolaryngology, M.G.M. Medical College and M.Y. Hospital, Indore, Madhya Pradesh, India.
4. Postgraduate Resident, Department of Radiodiagnosis, M.G.M. Medical College and M.Y. Hospital, Indore, Madhya Pradesh, India.
5. Postgraduate Resident, Department of Radiodiagnosis, M.G.M. Medical College and M.Y. Hospital, Indore, Madhya Pradesh, India.
6. Postgraduate Resident, Department of Radiodiagnosis, M.G.M. Medical College and M.Y. Hospital, Indore, Madhya Pradesh, India.

NAME, ADDRESS, E-MAIL ID OF THE CORRESPONDING AUTHOR:

Dr. Mrinal Choudhary,
Postgraduate Resident, Department of Radiodiagnosis, M.G.M. Medical College
and M.Y. Hospital, Indore-452001, Madhya Pradesh, India.
E-mail: choudharymrinal894@gmail.com

PLAGIARISM CHECKING METHODS: (Jan H et al.)

- Plagiarism X-checker: Mar 29, 2022
- Manual Googling: May 30, 2022
- iThenticate Software: Jun 24, 2022 (5%)

ETYMOLOGY: Author Origin

AUTHOR DECLARATION:

- Financial or Other Competing Interests: None
- Was Ethics Committee Approval obtained for this study? Yes
- Was informed consent obtained from the subjects involved in the study? Yes
- For any images presented appropriate consent has been obtained from the subjects. Yes

Date of Submission: **Mar 23, 2022**

Date of Peer Review: **Apr 24, 2022**

Date of Acceptance: **Jun 26, 2022**

Date of Publishing: **Jul 01, 2022**